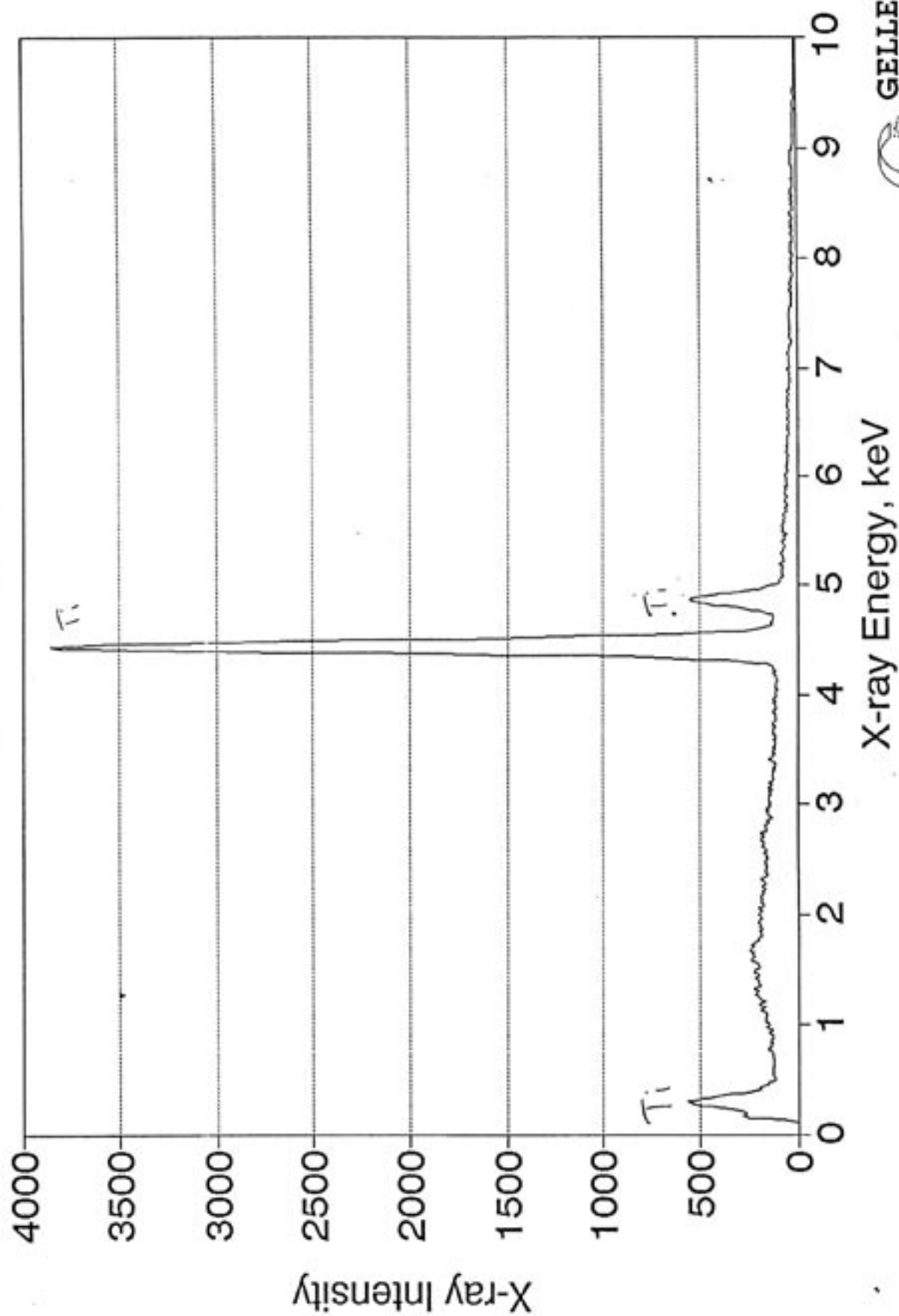
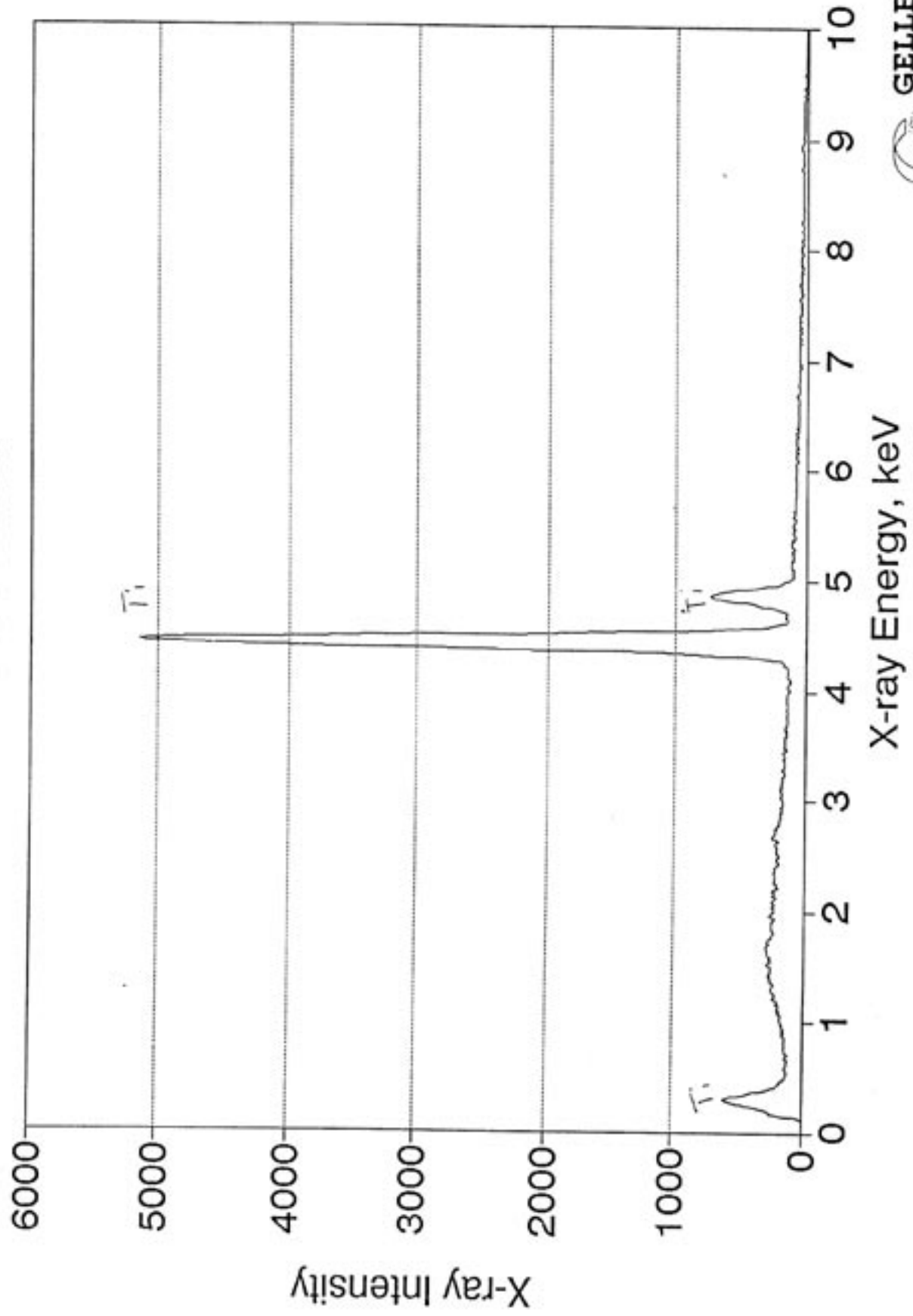


Surface State analysis
Jun 1994

4.75 X 7mm

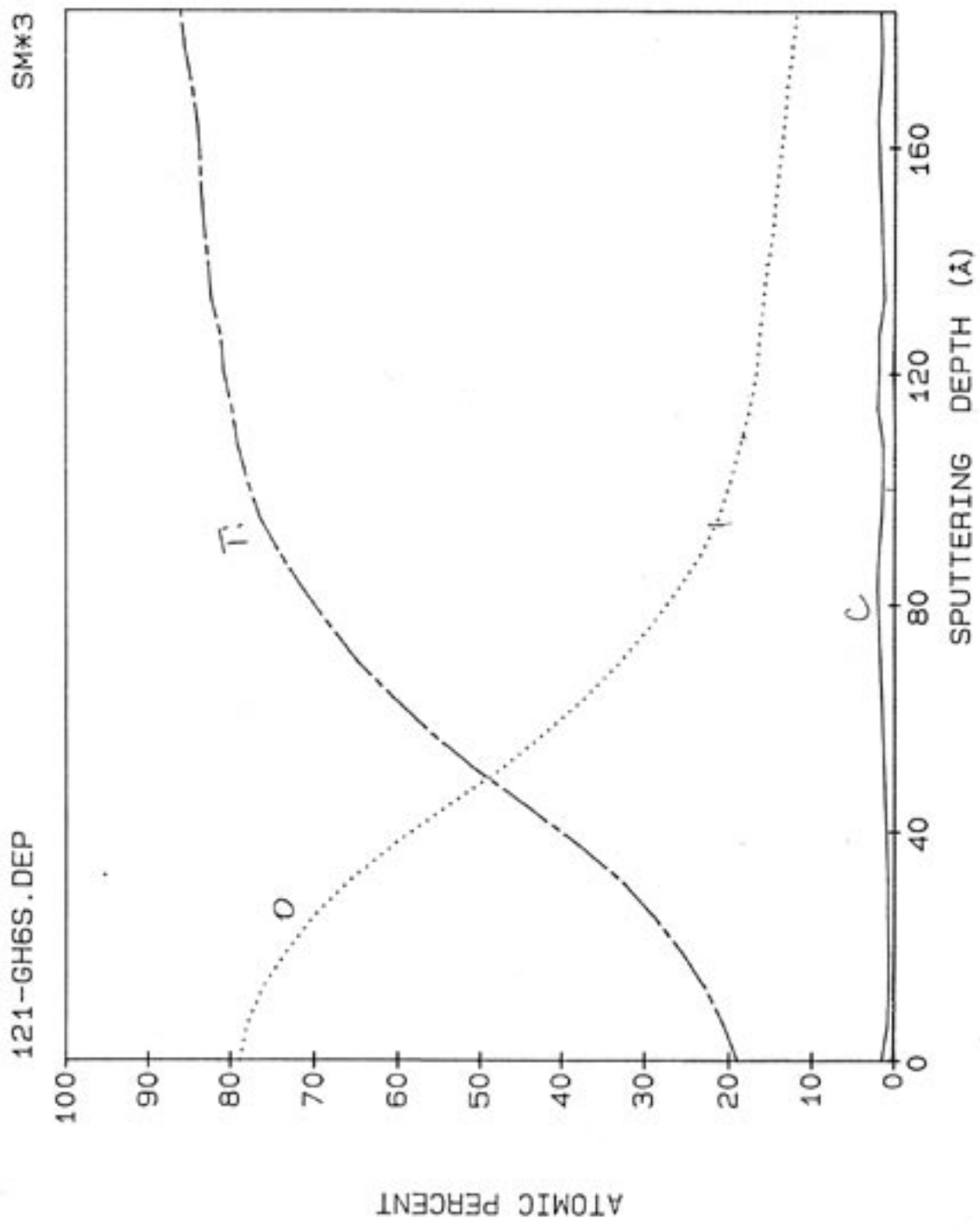


3.75 x 7.7mm



4.75 x 7 mm
~~3.75 x 7.7 mm~~

13-JUN-94



PEAK	SCALING FACTOR
C	1
CA	1
TI	1
O	1

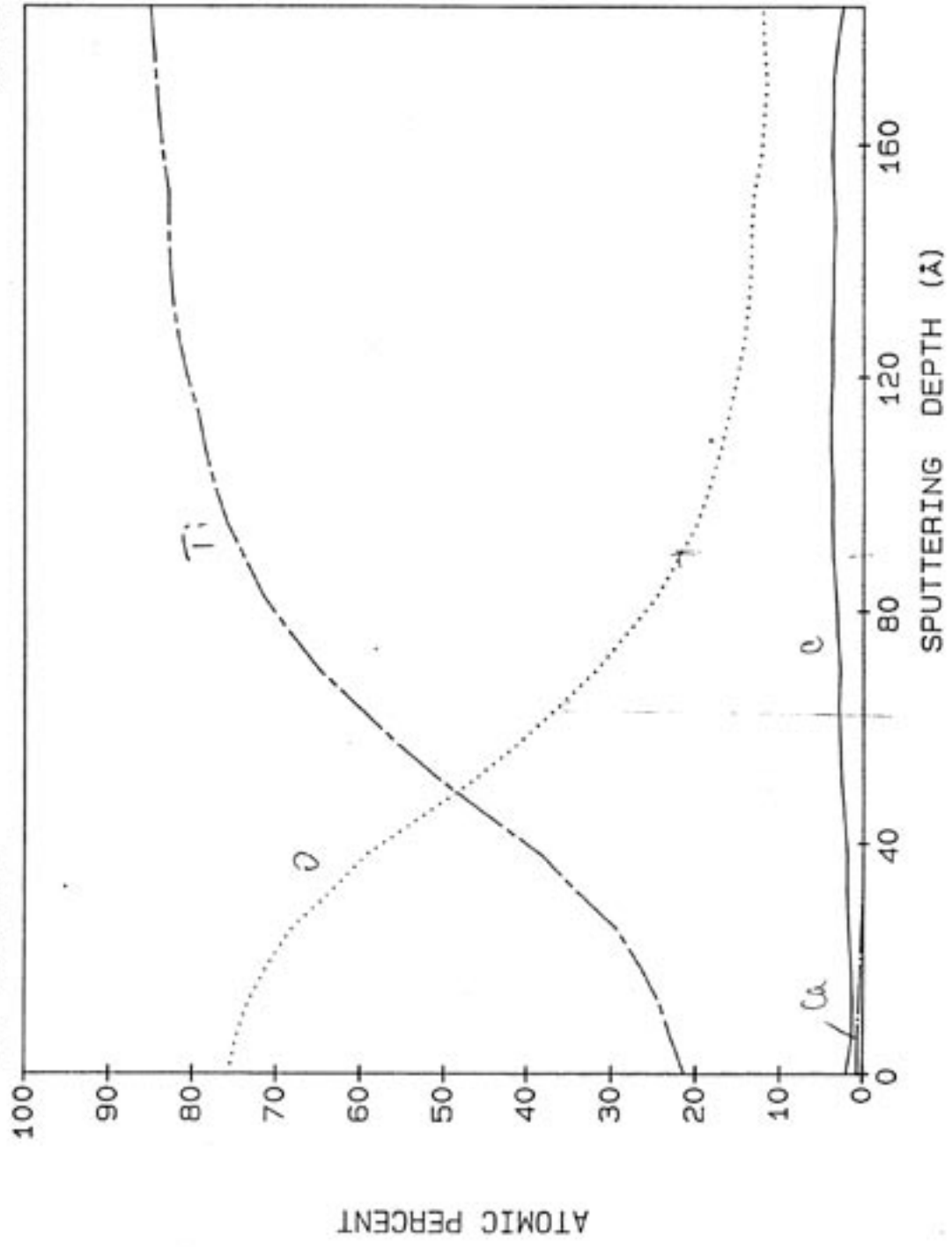
13-JUN-94

3.75 X 7.7MM

SM#3

121-GH5S.DEP

PEAK	SCALING FACTOR
C	1
CA	1
TI	1
O	1



SHORT PROGRESS REPORT:

Effect of lactoferrin on osseointegration and bone healing around the dental implant : An experimental study in pigs.

ABSTRACT:

In this study, uniform intrabony defects were created. Dental implants (EUROTEKNIKA AESTHETICA® , Sallanches,FRANCE) were placed into these defects. The remaining space around the implants were filled with bovine milk lactoferrin (SIGMA-ALDRICH®, Germany) containing microspheres and bovine hydroxyapatite bone grafts (UNILAB SURGIBONE® Mississauga,Ontario,CANADA). For this purpose , bony defects were created 10 mm in diameter and 4 mm in depth using trephine burs. 24 dental titanium implants were placed into these defects. The diameter of these implants were 3.6 mm and the length is 8 mm.. The specimens will be prepared for histomorphometric analysis. Newly formed bone, bone/graft ratio and bone implant contact will be measured.

The study groups are listed as follows:

- Group 1: Eight dental implants (EUROTEKNIKA AESTHETICA® , Sallanches,FRANCE) were placed into surgically created uniform bone defects which were filled with mixture of bovine hydroxiapatite bone graft and bovine lactoferrin. Defects were covered by resorbable collagen membrane(COLLAGENE AT®)
- Group 2: Eight dental implants (EUROTEKNIKA AESTHETICA® , Sallanches,FRANCE) were placed into surgically created uniform bone defects which were filled with bovine hydroxiapatite bone graft alone. Defects were covered by resorbable collagen membrane(COLLAGENE AT®)
- Group 3: Eight dental implants (EUROTEKNIKA AESTHETICA® , Sallanches,FRANCE) were placed into surgically created uniform bone defects which were remained unfilled. Defects were covered by resorbable collagen membrane (COLLAGENE AT®)

Histological preparation:

As mentioned above, twelve pigs were operated for this project successfully. All pigs remained healthy and healing was uneventful. Animals were sacrificed after eight weeks of bone healing in all groups. All specimens were removed from the pig calvarias and fixated in 10% buffered formalin.

After that, the twenty-four specimens will be embedded into methylnmethacrylate resin. The specimens will be sectioned by using EXAT[®] low speed diamond saw along the long axis of dental implant (~ 400 µm in thickness). The sections will be mounted on opaque Plexiglas with acrylic glue and ground to a final thickness of 50 µm. Finally the sections were superficially stained with toluidine blue. The sections will be analyzed histomorphometrically by the same examiner with BIOCOUNT[®] software. Three of clinical operation figures are as follows:

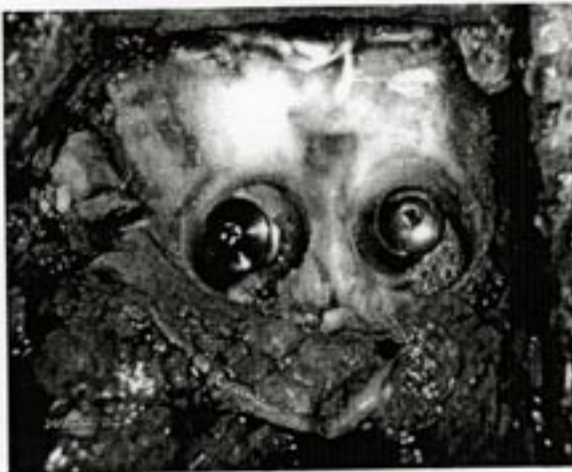

Figure 1 : Dental implants were placed into surgically created bone defects.

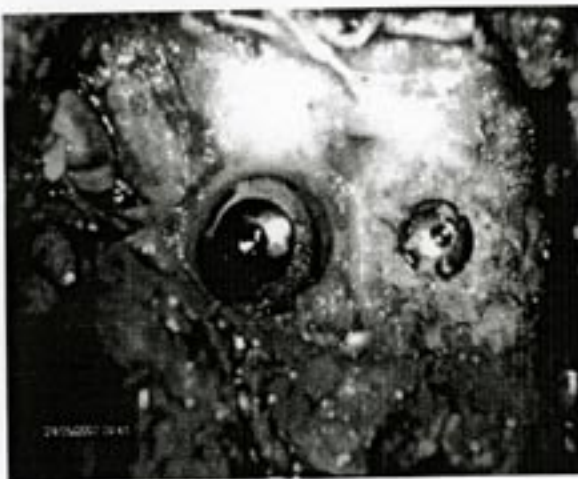

Figure 2 : The defect on the right side was filled with bovine bone hydroxiapatite




Figure 3: Each defect was covered with resorbable collagen membrane.

Researchers:

1. Mehmet KÜRKÇÜ , Associate professor
2. Ulaş GÖRMEZ, Resident